Darier Disease and Hailey–Hailey Disease 59

Daniel M. Hohl

Chapter Contents

Darier Disease 951
Hailey–Hailey Disease. 957

DARIER DISEASE

Synonyms: ■ Darier–White disease ■ Keratosis follicularis ■ Dyskeratosis follicularis

Key features

- Autosomal dominant disorder in which mutations in *ATP2A2* result in dysfunction of an endoplasmic reticulum Ca^{2+} ATPase (SERCA2), thus interfering with intracellular Ca^{2+} signaling
- Keratotic and crusted papules and plaques favor seborrheic areas; additional features include palmoplantar papules, variable nail changes, and whitish oral mucosal papules
- Clinical subtypes include an acral hemorrhagic variant and segmental forms due to type 1 and type 2 mosaicism
- Characterized histologically by acantholytic dyskeratosis with suprabasilar clefting, "corps ronds", and "grains"

Introduction

Darier disease is an autosomal dominant genodermatosis with characteristic mucocutaneous findings such as keratotic papules on the upper trunk and longitudinal erythronychia. Insufficient function of the 2b isoform of the sarco/endoplasmic reticulum Ca^{2+} ATPase (SERCA2b) leads to abnormal intracellular Ca^{2+} signaling, notably involving the endoplasmic reticulum. The result is a loss of suprabasilar cell adhesion (acantholysis) and an induction of apoptosis (dyskeratosis).

History

In 1889, the French dermatologist Jean Darier[1], at the Hôpital Saint-Louis in Paris, and James C. White[2], Professor of Dermatology at Harvard University, independently reported a skin disease characterized by brown, crusted, malodorous lesions with a follicular distribution. Darier called the disease "psorospermose folliculaire végétante" because of his histopathologic studies, where throughout the malpighian layer he saw a large number of round bodies surrounded by a double-layered membrane. He and others thought that these bodies represented psorosperms, a type of parasitic protozoa now referred to as coccidia, which they postulated were the causative agents for the disease. However, attempts to culture or inoculate the supposed parasites failed, and the histologic changes were subsequently recognized as sequelae of abnormal keratinization. The supposed follicular origin of the disease could not be confirmed either, as lesions were noted to occur outside the pilosebaceous unit. It was White who first suggested the hereditary character of the disorder, when the daughter of his initially described patient developed similar skin lesions.

Epidemiology

The reported prevalence of Darier disease ranges from 1 in 100 000 in Denmark to 1 in 30 000 in Scotland, and the estimated incidence is 4 per million per 10 years[3]. Men and women are equally affected. Darier disease has an autosomal dominant mode of inheritance with complete penetrance and variable expressivity. For example, in a series of 42 patients with Darier disease, 7 of 18 affected individuals who recalled no family history were found to be members of known Darier kindreds with mildly affected parents[4]. The clinical severity varies among different families carrying identical mutations and among members of the same family. Indeed, subtle changes of the skin or nails may remain unnoticed by affected persons.

Pathogenesis

Mutations in *ATP2A2* which encodes an endoplasmic reticulum (ER) Ca^{2+} ATPase pump, SERCA2, leads to both acantholysis and apoptosis, accounting for the characteristic histologic finding of acantholytic dyskeratosis. SERCA2 haploinsufficiency has been hypothesized to underlie the condition's dominant inheritance pattern[5], but a more recent study found that aggregates of mutant SERCA2 may exert a dominant negative effect by inducing ER stress and keratinocyte apoptosis[6]. Although both SERCA2a and SERCA2b isoforms are found within the epidermis, SERCA2b is the major protein product and its dysfunction alone can produce Darier disease[7]. While SERCA2 is ubiquitously expressed, a lack of compensatory SERCA3 expression in keratinocytes may explain the particular vulnerability of these cells to SERCA2 deficiency.

Close to 300 pathogenic *ATP2A2* mutations have been identified, primarily missense and frameshift alterations. In general, there is no clear genotype–phenotype correlation[8]. Likely exceptions include a particular *ATP2A2* mutation underlying the allelic acrokeratosis verruciformis of Hopf[9,10] (see below) and mutations in the S4-M4 region associated with more severe neuropsychiatric manifestations[11]. Several pathogenic mechanisms have been proposed for the acantholytic dyskeratosis of Darier disease. *ATP2A2* mutations result in chronically low Ca^{2+} stores within the ER (Fig. 59.1)[12], which is aggravated by cellular stress. This Ca^{2+} depletion leads to *acantholysis* via impaired processing, folding and trafficking of junctional proteins such as desmoplakin[13] and E-cadherin[14]. Impaired membrane translocation of protein kinase C α, an important Ca^{2+}-dependent regulatory enzyme that interacts with membrane phospholipids, is thought to mediate the disruption of desmosome assembly[15]. Studies have also shown that SERCA2 inhibition in keratinocytes causes increased levels of sphingosine, which inhibits protein kinase C α[14,16].

ER stress due to depleted Ca^{2+} stores and accumulation of unfolded proteins produces the "unfolded protein response", which can induce apoptosis[16,17]. ATP receptors, which are thought to have roles in apoptosis and calcium signaling, localize abnormally in lesional Darier disease epidermis, with decreased P2Y2 (a G protein-coupled receptor) but increased P2X7 (a death receptor) in the plasma membrane of acantholytic cells[18].

Clinical Features

Onset and clinical pattern

In ~70% of patients, Darier disease becomes apparent between the ages of 6 and 20 years, with a peak onset during puberty (ages 11–15 years)[19]. The primary lesions are keratotic, sometimes crusted, red to brown papules, which develop preferentially in a "seborrheic" distribution involving the trunk (Fig. 59.2), scalp (especially its margins; Fig. 59.3), face, and lateral aspects of the neck (Fig. 59.4). Despite its initial description as follicular dyskeratosis, the papules are not limited to a perifollicular location. The lesions tend to become confluent and may form papillomatous masses (Fig. 59.2B,D). Small (2–3 mm) hypomelanotic macules may be admixed with the keratotic papules

Downloaded for Anonymous User (n/a) at Egyptian Knowledge Bank from ClinicalKey.com by Elsevier on March 10, 2024. For personal use only. No other uses without permission. Copyright ©2024. Elsevier Inc. All rights reserved.

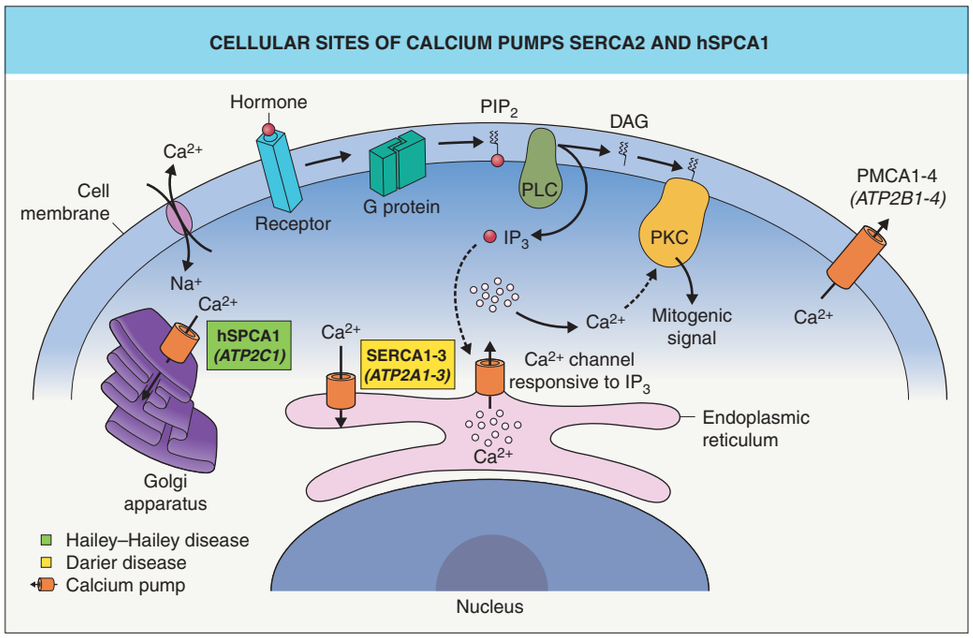

Fig. 59.1 Cellular sites of calcium pumps SERCA2 and hSPCA1. Darier disease is due to mutations in *ATP2A2* which encodes SERCA2. PIP_2, phosphoinositol diphosphate; IP_3, inositol triphosphate; PLC, phospholipase C; DAG, diacylglycerol; PKC, protein kinase C.

Fig. 59.2 Darier disease. A–D Truncal involvement with a predilection for seborrheic areas. Keratotic papules can vary from red (**A, B**) to brown (**C, D**) in color and may become confluent. **E** Papules with scale-crust and focal erosions on the leg. *A & C, Courtesy Julie V. Schaffer, MD; E, Courtesy Kalman Watsky, MD.*

Downloaded for Anonymous User (n/a) at Egyptian Knowledge Bank from ClinicalKey.com by Elsevier on March 10, 2024. For personal use only. No other uses without permission. Copyright ©2024. Elsevier Inc. All rights reserved.

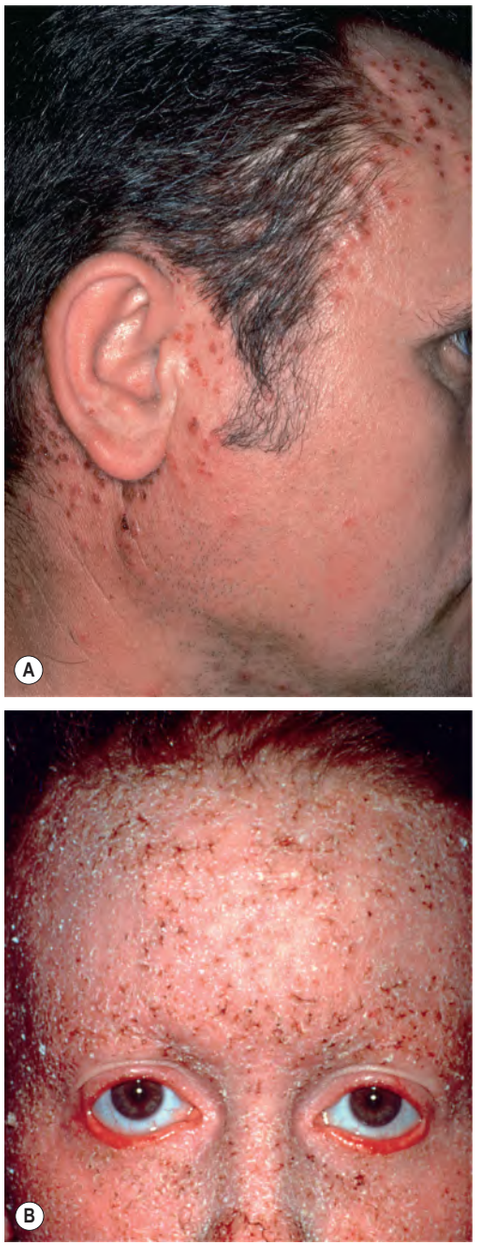

Fig. 59.3 Darier disease. A Crusted papules at the hairline on the face and in the posterior auricular area. **B** Extensive facial involvement leading to ectropion.

and occasionally are the predominant feature (Fig. 59.5). Rarely, sterile vesicles or bullae are prominent, and, in these cases, herpetic infection (Kaposi varicelliform eruption) must be excluded[20,21].

Most patients have lesions in the axillae, groin, and/or inframammary area (Fig. 59.6). Although these intertriginous lesions are usually mild, they are occasionally the predominant finding and may result in the misdiagnosis of Hailey–Hailey disease (HHD)[22]. Occasionally, macerated, fungating masses are seen in the axillae or groin. Malodor is a frequent and distressing feature of Darier disease.

In ~50% of patients, 2–4 mm, skin-colored or brownish, flat-topped papules, reminiscent of flat warts, are found on the dorsal aspects of the hands and feet, and less often, on the forearms and legs (Fig. 59.7). Rarely, acral hemorrhagic vesicles may also be seen. Palmoplantar papules, many of which are keratotic, and keratin-filled depressions are almost invariably present (Fig. 59.8). Subtle changes can be detected by obtaining finger or palm prints, which show interruption of the dermatoglyphic pattern. Nail changes include longitudinal red and/or white lines, longitudinal ridging and fissuring, and wedge-shaped subungual hyperkeratosis (Fig. 59.9). The nails are brittle and tend to break distally, forming V-shaped notches[23].

Painless whitish papules or rugose plaques are noted on the oral mucosa in 15%–50% of patients with Darier disease. The hard palate is the most common site of involvement, followed by the gingiva, buccal mucosa, and tongue (Fig. 59.10)[19].

Symptoms

Most patients complain of moderate itching. Equally distressing are the appearance and the odor, which can lead to social isolation.

Modifying factors

This condition frequently worsens during the summer. In patients with Darier disease, characteristic lesions can be experimentally induced in clinically uninvolved skin by UV irradiation, and UVB irradiation has been shown to suppress *ATP2A2* expression in keratinocytes[23]. Sweating, heat, and occlusion represent additional factors that trigger exacerbations primarily in covered and intertriginous areas (e.g. after a long airplane flight), and this predisposes patients to infections (see below). Interferon β-1a or lithium carbonate[24,25] can provoke flares of Darier disease.

Course of the disease

Darier disease follows a chronic course with fluctuations in disease severity. While some patients report improvement over time, others experience worsening.

Infectious complications

Areas of skin affected by Darier disease are prone to secondary infections with bacteria, yeast, and dermatophytes, often leading to malodor and vegetating plaques. A study of 75 adult patients found a high prevalence of *Staphylococcus aureus* colonization in lesional skin (~70%) and the nares (~50%), which correlated with a more severe phenotype[26].

Affected individuals are also susceptible to the development of widespread cutaneous infections with human papillomaviruses (HPV) and herpes simplex virus (HSV). When there is a sudden onset and rapid spread of vesicular and crusted lesions, often accompanied by fever and malaise, the clinician should have a high index of suspicion for the development of Kaposi varicelliform eruption (KVE; Fig. 59.11)[21]. The latter requires systemic antiviral therapy (e.g. valacyclovir, acyclovir). Generalized cowpox infection has also been reported.

Disruption of the epidermal barrier likely plays an important role in the increased frequency and severity of skin infections in patients with Darier disease. Immunologic studies have shown no consistent systemic abnormalities[27]. However, an immunohistochemical analysis found evidence for an impaired local immune response, with a decrease in Langerhans cells and plasmacytoid dendritic cells[28]. In a recent study, SERCA2 activity was shown to be required for efficient V(D)J recombination, and 6/16 patients with Darier disease were found to have an abnormally low proportion of $CD19^+$ B cells in their peripheral blood lymphocytes[29].

Salivary glands

In some patients, obstruction of salivary gland ducts can lead to painful glandular swelling. Darier-like histologic changes within the ducts are thought to be responsible for the obstruction[30].

Neuropsychiatric disorders

Various neuropsychiatric conditions such as intellectual impairment, mood disorders, and epilepsy have been reported in association with Darier disease. Neuropsychiatric assessment of Darier disease patients from the UK revealed higher lifetime rates of major depression (30%), suicide attempts (13%), bipolar disorder (4%), and epilepsy (3%) than in the general population[31]. In a study based on the Swedish national registry, Darier disease patients (n = 770) were more likely to be diagnosed with intellectual disability (6.2-fold), bipolar disorder (4.3-fold), and schizophrenia (2.3-fold) than matched individuals from the general population[32].

More severe neuropsychiatric manifestations have been observed in patients with *ATP2A2* mutations in the S4-M4 region[11,31]. *ATP2A2* is expressed in the brain, and hypotheses regarding potential mechanisms for neuropsychiatric findings in Darier disease include disruption of intracellular calcium signaling, an impaired endoplasmic reticulum stress response, and accumulation of insoluble SERCA2 aggregates within neurons[6,11]. In addition, the disfigurement and social isolation associated with severe skin conditions often lead to psychological morbidity, which may contribute to depression and suicidal ideation in patients with Darier disease[22].

Downloaded for Anonymous User (n/a) at Egyptian Knowledge Bank from ClinicalKey.com by Elsevier on March 10, 2024. For personal use only. No other uses without permission. Copyright ©2024. Elsevier Inc. All rights reserved.

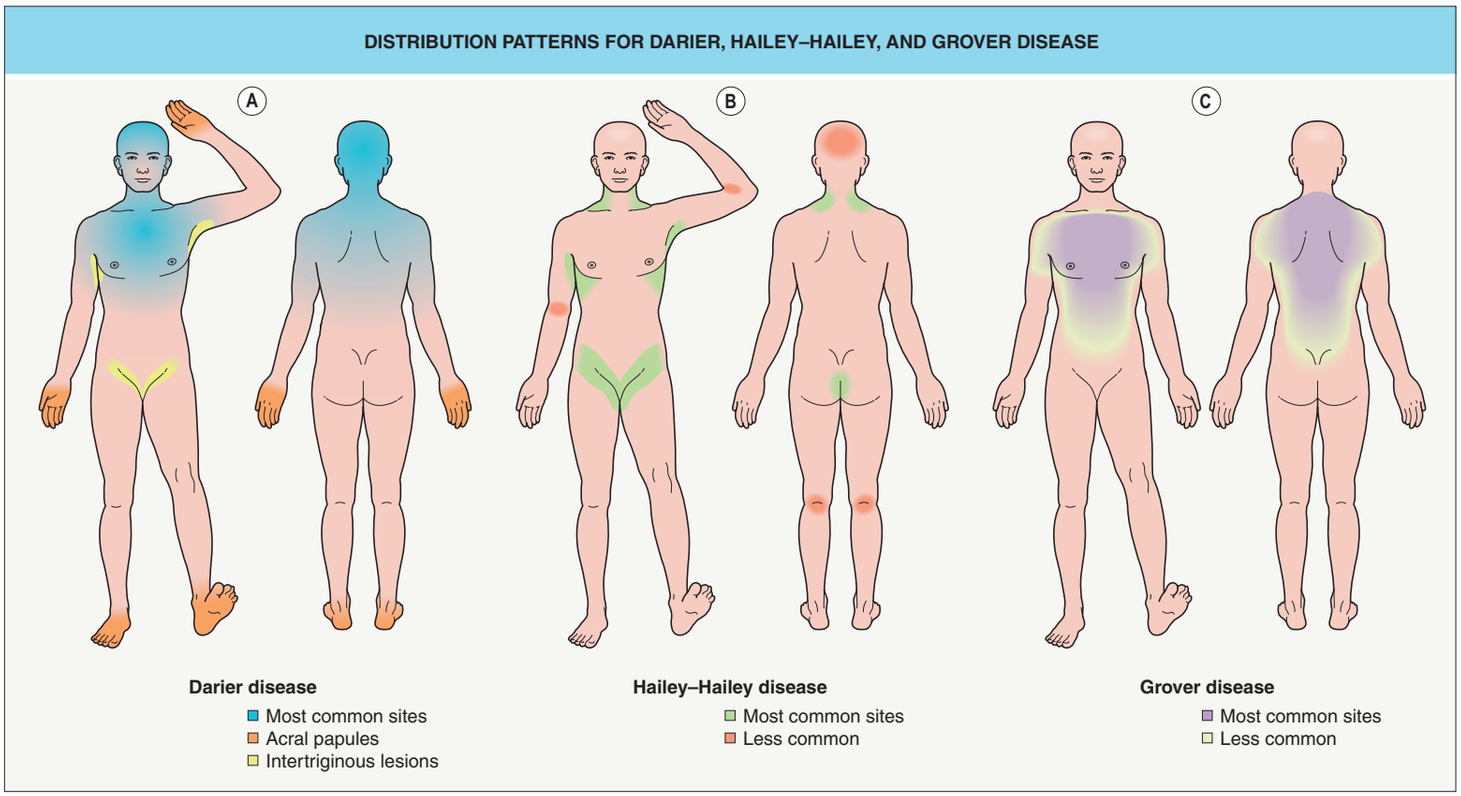

Fig. 59.4 Distribution patterns for Darier, Hailey–Hailey, and Grover disease.

Fig. 59.5 Darier disease. Observed most commonly in individuals with darkly pigmented skin, a guttate leukoderma may be seen in patients with Darier disease, including the segmental form. *Courtesy Julie V. Schaffer, MD.*

Fig. 59.6 Darier disease. Severe involvement in intertriginous zones, including the abdominal fold and groin.

Others

Dry eyes and blepharitis are common in patients with Darier disease[33], although more serious ocular complications, e.g. corneal ulcerations or staphylococcal endophthalmitis, are rare. There have been a few reports of squamous cell carcinomas arising in cutaneous or mucosal sites chronically affected by Darier disease[34]. Malignant transformation is a rare event and may be related to infection with oncogenic types of HPV or changes in keratinocyte adhesion and proliferation secondary to SERCA2 haploinsufficiency, which has been associated with squamous cell carcinomas of the skin and upper gastrointestinal tract in mice. Swedish cross-sectional case–control and population-based studies have suggested that Darier disease is associated with an increased risk of heart failure and type 1 diabetes mellitus[35]. Observations of bone cysts, renal agenesis, and autoimmune thyroiditis in patients with Darier disease are thought to represent chance associations.

Clinical subtypes of darier disease

Acral hemorrhagic type (Table 59.1)

In addition to classic clinical features, a small subset of patients develop sharply demarcated, red to blue–black macules on the palms and soles as well as the dorsal aspects of the hands. These irregularly shaped lesions represent hemorrhage into acantholytic vesicles. A particular *ATP2A2* missense mutation (N767S) has been identified in several non-related families with the acral hemorrhagic type of Darier disease[11], as well as in individuals with a classic Darier disease phenotype[8].

Segmental types 1 and 2

Two types of segmental Darier disease have been described, both with a distribution of lesions along the lines of Blaschko (see Ch. 62). With the more common type 1 mosaicism (Fig. 59.12), the age of onset, severity, and histologic findings within the streaks are similar to those of generalized Darier disease. Type 1 segmental Darier disease results from a postzygotic mutation in *ATP2A2* during embryogenesis, which leads to a mosaic pattern of skin involvement. Heterozygous *ATP2A2*

Downloaded for Anonymous User (n/a) at Egyptian Knowledge Bank from ClinicalKey.com by Elsevier on March 10, 2024. For personal use only. No other uses without permission. Copyright ©2024. Elsevier Inc. All rights reserved.

Fig. 59.7 Darier disease. Multiple flat-topped papules on the dorsal aspect of the hand.

Fig. 59.9 Darier disease. Alternating longitudinal red and white streaks as well as notching of the free edge of the nail plate. *Courtesy Antonella Tosti, MD.*

Fig. 59.8 Palmar involvement in Darier disease. A Both keratotic papules and keratin-filled depressions are seen. **B** Less commonly, a thick, spiked focal keratoderma is observed. *A, Courtesy Kalman Watsky, MD; B, Courtesy Julie V. Schaffer, MD.*

Fig. 59.10 Oral mucosal Darier disease. Whitish papules on the palate.

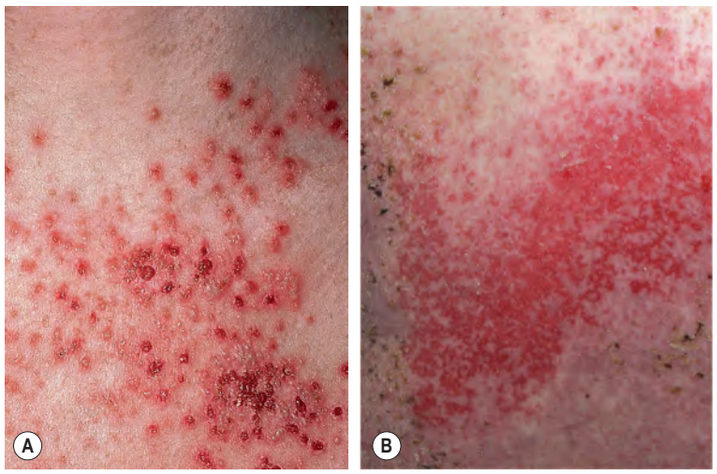

Fig. 59.11 Darier disease with superimposed HSV infection (Kaposi varicelliform eruption). Multiple hemorrhagic crusts (**A**) and punched-out erosions (**B**) of a similar size are seen. *B, Courtesy Kalman Watsky, MD.*

mutations in affected, but not background, skin have been documented in patients with this form of segmental Darier disease[36]. If there are mutant cells in the gonads, a patient with type 1 segmental manifestations may have offspring with generalized Darier disease.

Patients with type 2 mosaicism have generalized Darier disease plus linear streak(s) with increased severity[37]. Type 2 segmental manifestations of autosomal dominant disorders occur when patients with a heterozygous germline mutation also have a postzygotic inactivating mutation in the *other* allele of the same gene (i.e. a "second hit" causing loss of heterozygosity), which leads to more severe manifestations in a mosaic distribution (see Fig. 62.2). Of note, a second hit in *ATP2A2* was identified in skin from erosive patches following the lines of Blaschko in a 1-year-old boy with a family history of Darier disease[38].

Downloaded for Anonymous User (n/a) at Egyptian Knowledge Bank from ClinicalKey.com by Elsevier on March 10, 2024. For personal use only. No other uses without permission. Copyright ©2024. Elsevier Inc. All rights reserved.

LESS COMMON PRESENTATIONS OF DARIER DISEASE
Morphologic variants
• Guttate hypopigmentation (see Fig. 59.5) > hyperpigmented flat-topped papules and macules ("freckle-like")*
• Vesiculobullous lesions
• Acral hemorrhagic lesions
• Keratoderma (spiked; see Fig. 59.8B)
• "Cornifying" (e.g. with cutaneous horns)
• Comedones†, facial cysts, acne conglobata
• Periocular nodulocystic lesions
• Alopecia, cutis verticis gyrata
Distribution patterns
• Predominantly involving intertriginous areas, sun-exposed skin, the extremities, acral sites, or the scalp (pityriasis amiantacea-like)
• Segmental (type 1 > 2) (see Fig. 59.12)
Extracutaneous
• Oral mucosal erosions
• Corneal opacities or ulcers
• Salivary gland obstruction
• Laryngeal involvement
*A persistent acantholytic dermatosis and extensive lentiginous "freckling" without an underlying *ATP2A2* mutation has also been described.
†The differential diagnosis may include familial dyskeratotic comedones.

Table 59.1 Less common presentations of Darier disease.

Fig. 59.12 Type 1 segmental Darier disease. Note the distribution of the papules along the lines of Blaschko.

Pathology

There are two prominent histologic features in Darier disease, acantholysis and dyskeratosis (Fig. 59.13). Acantholysis is due to a disturbance in cell adhesion that leads to suprabasilar cleft formation. At the ultrastructural level, this corresponds to a loss of desmosomes and detachment of keratin filaments from the desmosomes[39]. Dyskeratosis is due to apoptosis of keratinocytes and is characterized by nuclear condensation and perinuclear keratin clumping. Two types of dyskeratotic cells are observed in Darier disease[40]:

- "Corps ronds" – acantholytic enlarged keratinocytes in the malpighian layer with darkly staining and partially fragmented nuclei surrounded by a clear cytoplasm and encircled by a bright ring of collapsed keratin bundles.

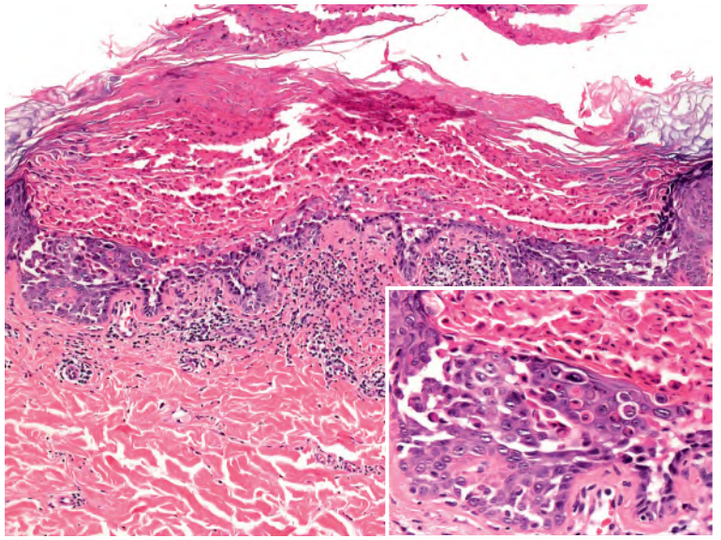

Fig. 59.13 Histopathology of Darier disease. Hyperkeratosis, grains and corp ronds (inset) are seen in addition to acantholysis leading to suprabasilar clefting. *Courtesy Lorenzo Cerroni, MD.*

- "Grains" – small, oval cells in the stratum corneum characterized by an intensely eosinophilic cytoplasm composed of collapsed keratin bundles containing shrunken parakeratotic nuclear remnants. "Grains" are likely derived from "corps ronds", but formal proof that they indeed represent different stages of the same pathologic process has not been provided.

The epidermis overlying acantholytic and dyskeratotic foci is thickened and shows papillomatosis and hyperkeratosis. In the superficial dermis, there is a mild to moderate perivascular inflammatory infiltrate. Diagnostic histologic changes are often focal, necessitating a careful search. Similar histologic features may be observed in Grover disease, but in the latter there tends to be more acantholysis, less dyskeratosis, and fewer "corps ronds" or "grains". The two conditions can be histologically indistinguishable, but the findings are typically broader in Darier disease, i.e. in a given biopsy specimen a larger portion of the epidermis is affected, sometimes with skip areas. Presence of eosinophils within the inflammatory infiltrate favors Grover disease.

Differential Diagnosis

Acrokeratosis verruciformis of Hopf

Flat-topped, wart-like papules on the dorsal aspects of the extremities are a common manifestation of Darier disease. They are clinically indistinguishable from the lesions that characterize the autosomal dominant disorder described by Hopf as "acrokeratosis verruciformis" (Fig. 59.14)[41]. There has been debate as to whether acrokeratosis verruciformis is a separate entity or an allelic forme fruste of Darier disease. A particular *ATP2A2* missense mutation that leads to Pro602Leu in SERCA2 has been identified in families with isolated acrokeratosis verruciformis as well as a Swiss kindred with acral warty lesions followed by the development of more widespread papules after intense sun exposure (author's unpublished observation), but not classic Darier disease[9,10].

Acrokeratosis verruciformis and Darier disease have traditionally been separated on the basis of their histologic features, with the former lacking acantholysis and dyskeratosis. However, serial sectioning is often required to find foci of acantholysis and dyskeratosis in acral skin biopsy specimens from patients with Darier disease[42]. In addition, Hopf actually described nail changes and palmoplantar keratotic papules in his initial report of acrokeratosis verruciformis[41], and there have been subsequent observations of families where some members had only acrokeratosis verruciformis while others exhibited the classic skin findings of Darier disease[43]. Because patients with Darier disease often develop warty lesions on the extremities before keratotic papules appear in a seborrheic distribution, some individuals who present with acrokeratosis verruciformis may later be diagnosed as actually having Darier disease[4].

Downloaded for Anonymous User (n/a) at Egyptian Knowledge Bank from ClinicalKey.com by Elsevier on March 10, 2024. For personal use only. No other uses without permission. Copyright ©2024. Elsevier Inc. All rights reserved.

Fig. 59.14 Acrokeratosis verruciformis of Hopf. Involvement of the dorsal aspect of the foot with flat-topped papules.

Other conditions

Although the clinical differential diagnosis may include severe seborrheic dermatitis and Grover disease (transient acantholytic dermatosis; see Fig. 59.4 and Ch. 87), Darier disease is readily distinguished by involvement of acral skin, the nails, and the oral mucosa. A family history may also be a clue to the diagnosis of Darier disease, and histologic findings differentiate it from seborrheic dermatitis. In Grover disease, the pruritic crusted papules are not confluent, and they typically develop after occlusion and/or sweating. However, in a persistent form of acantholytic dermatosis that affects patients with significant actinic damage, the papules are scalier and the histologic features closely resemble those of Darier disease[44].

In patients with predominantly flexural involvement, pemphigus vegetans (Hallopeau type), pemphigoid vegetans, blastomycosis-like pyoderma (pyoderma vegetans), and HHD may represent diagnostic considerations. Pemphigus vegetans usually develops at an older age and is characterized histologically by exocytosis of eosinophils as well as acantholysis but not dyskeratosis; direct immunofluorescence (DIF) shows the intercellular pattern of the pemphigus group, and anti-desmoglein antibodies can be detected by ELISA. Pyoderma vegetans features a neutrophilic infiltrate, and acantholysis is not observed. HHD is sometimes difficult to separate clinically from primarily intertriginous Darier disease. The presence of palmoplantar papules, longitudinal erythronychia, distal notching of the nails, mucosal lesions, and prominent dyskeratosis as well as acantholysis histologically can serve as clues to the diagnosis of Darier disease. Occasionally, a sporadic disorder referred to as "papular acantholytic dyskeratosis" may be localized to the vulvocrural area and in an affected individual, identical somatic *ATP2A2* mutations have been detected within the papules.

Treatment

General measures

Therapies directed against hyperkeratosis, inflammation, and infection are employed as needed. Lightweight clothes and sun protection help prevent aggravation due to heat, sweating, and exposure to UV radiation. Skin care includes the use of antimicrobial cleansers and/or bleach baths (0.5 cup of household bleach [6%–8.25% sodium hypochlorite] in a full standard bathtub once or twice weekly) to prevent malodorous bacterial colonization as well as keratolytic emollients to reduce scaling and irritation.

Topical and intralesional therapy

Topical retinoids are more effective as monotherapy[45,46] than topical vitamin D analogues[47], which had no benefit in a small randomized controlled study[48], or corticosteroids. However, retinoid-associated irritation is common and can be reduced by alternate-day application, liberal use of emollients[45,49], and combination therapy with mid-potency topical corticosteroids[45,49]. Improvement following treatment with topical calcineurin inhibitors has also been reported[48]. Intermittent use of topical antibiotics and antifungal agents is helpful in reducing malodor due to microbial colonization and mild secondary infections.

Several case reports have suggested that topical 5-fluorouracil (1% or 5%) may be efficacious alone or in combination with oral alitretinoin (see below)[50]. Benefit from topical application of diclofenac sodium 3% gel has also been described[51], and cyclooxygenase-2 (COX-2) inhibition has been shown to rescue keratinocytes from UVB-induced downregulation of *ATP2A2* expression[52].

Systemic therapy

Isotretinoin, acitretin, and alitretinoin represent effective treatments for Darier disease, producing significant improvement in ~90% of patients[22,53]. However, the use of these agents is limited by their side effects, and relapse occurs after cessation of therapy. Thus, it is generally recommended that systemic retinoids be reserved for patients with severe disease unresponsive to topical treatment. Because of the teratogenic potential of systemic retinoids, contraception is mandatory for women of childbearing potential (see Ch. 126). Individual dose titration is important to optimize the benefit–risk balance and avoid excessive dose-related side effects, such as mucocutaneous dryness and elevation of serum lipids. Intermittent therapy to prevent exacerbations during the summer months is a useful approach. In patients with predominantly bullous or intertriginous lesions, oral retinoids may aggravate the disease and are not recommended[54].

Oral contraceptives may mitigate symptoms in women with premenstrual exacerbations[55]. Cyclosporine represents an option for patients with severe Darier disease who cannot tolerate or do not respond to oral retinoids[56]. Low-dose intravenous immunoglobulin was also reported to reduce crusting and pruritus in a patient with Darier disease[57]. Oral antibiotics and antifungal medications are often required for significant infections, and oral antivirals (e.g. valacyclovir) are necessary for KVE.

Surgical therapy

Surgical therapy may be an effective alternative for focal recalcitrant lesions, particularly in the flexural and gluteal areas. Excision followed by split-thickness grafting, dermabrasion, or laser removal (CO_2 or erbium:YAG) may yield a long-term remission[58]. Destructive treatment must include the follicular infundibulum in order to prevent recurrences. Experience is necessary to avoid scarring, particularly in body areas at risk for hypertrophic scar or keloid formation. From this standpoint, the erbium:YAG laser might have an advantage over the CO_2 laser[59]. In small case series, improvement has been observed following pulsed dye laser and photodynamic therapy[60].

HAILEY–HAILEY DISEASE

Synonym: ■ Familial benign chronic pemphigus

Key features

- An uncommon autosomal dominant disorder in which mutations in *ATP2C1* result in dysfunction of a Golgi-associated Ca^{2+} ATPase, thus interfering with intracellular Ca^{2+} signaling
- Clinically, flaccid blisters and erosions are seen in intertriginous areas, especially the axillae and groin; moist, malodorous vegetations and fissures may develop
- Segmental variants (types 1 and 2 mosaicism) can occur
- The major histologic finding is acantholysis throughout the spinous layer, sometimes referred to as a "dilapidated brick wall"

Introduction

HHD is an autosomal dominant genodermatosis characterized by vesicular and erosive lesions that favor the intertriginous areas,

Downloaded for Anonymous User (n/a) at Egyptian Knowledge Bank from ClinicalKey.com by Elsevier on March 10, 2024. For personal use only. No other uses without permission. Copyright ©2024. Elsevier Inc. All rights reserved.

especially the axillae and groin. Mutations in *ATP2C1*, which encodes the Golgi-associated Ca^{2+} ATPase hSPCA1, lead to abnormal intracellular Ca^{2+} signaling, resulting primarily in a loss of cellular adhesion (acantholysis) in the stratum spinosum.

History

In 1939, Howard and Hugh Hailey, brothers working in the Department of Dermatology at Emory University School of Medicine in Atlanta, Georgia, described a chronic dermatosis in two sets of brothers. The disorder was characterized by recurrent blisters and erosive, crusted lesions on the neck (in one pair of brothers) and in the axillae and groin (in the second pair)[61]. Histologic sections from all four patients showed similar features – intraepidermal vesicles, mild dyskeratosis, hyperkeratosis, and a moderate dermal lymphocytic infiltrate. Different dermatopathologists interpreted these findings variably as pemphigus, pemphigus-like, or Darier disease. The authors themselves rightly believed that they were dealing with a novel entity separate from Darier disease and coined the name "familial benign chronic pemphigus".

A disease called "pemphigus congénital familiale héréditaire" had been described 6 years prior to the report by the Hailey brothers. Therefore, some believe that HHD should also bear the name of the French dermatologists Gougerot and Allée. However, they did not perform a biopsy, and the early onset and initial localization on pressure points suggest that their patients may have actually suffered from epidermolysis bullosa simplex[62]. The subsequent controversy as to whether "familial benign chronic pemphigus" was a distinct disorder or a phenotypic variant of Darier disease was eventually solved by our understanding of the molecular genetics of both disorders.

Epidemiology

There are no data regarding the exact prevalence of HHD. Based upon clinical experience, HHD is seen nearly as often as Darier disease. The mode of inheritance is autosomal dominant with complete penetrance, but the age of onset and expressivity vary markedly amongst affected family members[63,64]. Particular mutations may be associated with primarily genitoperineal involvement[65] or milder phenotypes[66].

Pathogenesis

HHD is caused by mutations in *ATP2C1*[67,68], which encodes hSPCA1, a Ca^{2+} ATPase that is localized to the Golgi apparatus[69,70] (see Fig. 59.1). hSPCA1 transports Ca^{2+} and Mn^{2+}, and it sequesters Ca^{2+} within the Golgi lumen. HHD is likely caused by haploinsufficiency and most *ATP2C1* mutations encode premature termination codons[71,72].

Acantholysis due to *ATP2C1* mutations appears to be mediated via impaired Ca^{2+} sequestration, resulting in depletion of Ca^{2+} within the Golgi lumen[69]. Normal Golgi Ca^{2+} levels are required for proper protein processing[73], and Golgi Ca^{2+} depletion in HHD keratinocytes impairs the processing and translocation of junctional proteins that function in cell–cell adhesion. Lesional skin from HHD patients shows decreased staining for extracellular desmosomal components[74], and altered synthesis of tight junction proteins has been observed in hSPCA1-deficient keratinocytes[75]. Reduced ATP levels in HHD keratinocytes have also been associated with impaired actin reorganization, which may affect adherens junction formation[76]. Lastly, decreased calcium levels in basal keratinocytes of lesional HHD epidermis may be linked to abnormal localization of ATP receptors and aberrant expression of keratins 10 and 14[18].

Clinical Features

Onset and clinical pattern

The initial lesions and associated symptoms usually develop during the second or third decade of life but may be delayed until the fourth or fifth decade[63]. HHD has a predilection for intertriginous sites, such as the axillae, groin, lateral aspects of the neck, and perianal region (Fig. 59.15A & C; see Fig. 59.4). The scalp, antecubital and popliteal fossae, and trunk are less frequently involved[77] (Fig. 59.15D). Inframammary and vulvar lesions are common in women (Fig. 59.15B), and female patients occasionally present with isolated vulvar disease[78].

The primary lesion is a flaccid vesicle on erythematous or normal-appearing skin, which ruptures easily and therefore is often overlooked (see Fig. 59.15A). The blisters give rise to macerated or crusted erosions (see Fig. 59.15B–D), which tend to spread peripherally, producing a circinate border with crusts and small vesicles when examined carefully

Fig. 59.15 Hailey–Hailey disease. A Erythematous, eroded plaque in the axilla. Note the intact flaccid vesicles at 2 and 7 o'clock. **B** Chronic submammary lesion with erosions in a worm-eaten pattern. **C, D** Vegetative plaques with erosions on the neck (**C**) and central chest (**D**). *C, D, Courtesy Jonathan S. Leventhal, MD.*

Downloaded for Anonymous User (n/a) at Egyptian Knowledge Bank from ClinicalKey.com by Elsevier on March 10, 2024. For personal use only. No other uses without permission. Copyright ©2024. Elsevier Inc. All rights reserved.

Fig. 59.16 Hailey–Hailey disease. Circinate plaques on the back with erosions and crusting in the active borders. *Courtesy Louis A. Fragola, Jr, MD.*

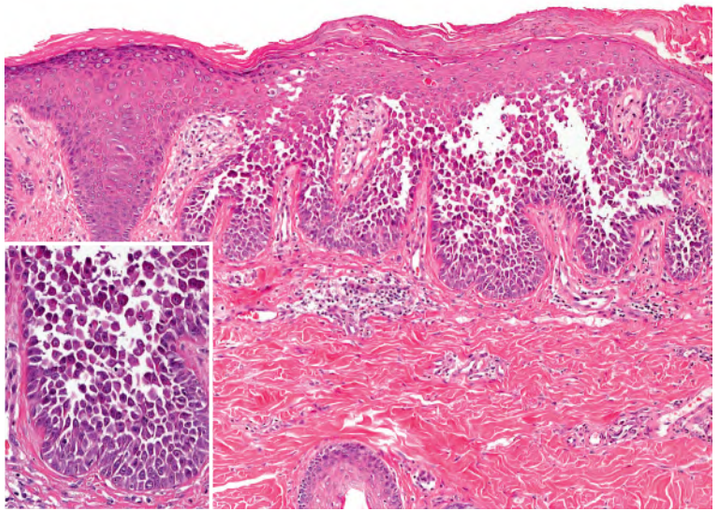

Fig. 59.17 Histopathology of Hailey–Hailey disease. Focal crusting and acantholysis beginning in the suprabasilar area and extending throughout the epidermis. The latter has been likened to a "dilapidated brick wall". *Courtesy Lorenzo Cerroni, MD.*

(Fig. 59.16). Development of chronic, moist, malodorous vegetations and painful fissures is common. Healing occurs without scarring, leaving postinflammatory hyperpigmentation.

Longitudinal leukonychia of the fingernails may serve as a subtle diagnostic clue in patients with limited or atypical disease[79]. Involvement of the buccal, vaginal, or conjunctival mucosae is rare[80–82].

Symptoms

Painful intertriginous erosions and crusting may interfere with activities of daily living. Fetid odor and pruritus add to the psychosocial distress experienced by HHD patients.

Modifying factors

Given the abnormal cell–cell adhesion within the epidermis, friction can induce new lesions. Heat and sweating can also exacerbate HHD, and patients often note worsening during the summer months. Although *ATP2C1* mRNA expression in keratinocytes can be suppressed by UVB irradiation[23], UV exposure does not appear to influence the course of HHD[63]. Microbial colonization and secondary infections are important modifying factors, as discussed below. In particular, staphylococcal infection potentiates acantholysis and may lead to severe and widespread blistering[83].

Course of the disease

Complete remissions as well as flares are common, and the clinical course in an individual patient is difficult to predict. Some patients report attenuation of the disease at an older age, whereas others experience no change or worsening over time[77]. Life expectancy is not altered.

Complications

Infections

As in Darier disease, colonization and secondary bacterial, fungal, and viral infections play an important role in disease exacerbation and persistence[84,85]. Vegetating lesions and malodor suggest bacterial and/or fungal overgrowth. Topical and/or systemic antimicrobial agents may be required to induce a clinical remission.

Recalcitrant intertriginous lesions have been described in association with HSV infections[84]. PCR-based testing, direct fluorescent antibody assays, or viral culture of infected keratinocytes can confirm this diagnosis; occasionally, a skin biopsy is required. KVE due to HSV is a rare complication of HHD[86]. It is characterized by fever and a rapidly spreading vesicular eruption, and prompt treatment with a systemic antiviral medication (e.g. valacyclovir, acyclovir) is required.

Malignant transformation

There are a few case reports of cutaneous squamous cell carcinoma developing within chronic lesions of HHD in the anogenital region[87]. It is possible that impairment of the structural integrity of the epidermis may predispose patients to infection with oncogenic strains of HPV (see Ch. 79).

Clinical subtypes of Hailey–Hailey disease

Segmental type 1

Segmental type 1 HHD is caused by a heterozygous postzygotic mutation in an otherwise normal embryo, resulting in a mosaic distribution of disease with age of onset and severity similar to the non-mosaic phenotype. Only a few cases of segmental type 1 involvement in HHD have been reported.

Segmental type 2

There are rare patients with generalized HHD who also have a segmental area of more pronounced involvement with earlier onset, analogous to type 2 segmental lesions described previously for Darier disease. This results from postzygotic inactivation of the normal *ATP2C1* allele (loss of heterozygosity), which leads to more severe disease in a mosaic pattern[88]. Unlike HHD due to a heterozygous mutation, the affected segments display acantholysis within adnexal structures, which might make it impossible to eradicate foci of blistering using superficial ablative methods (see below).

Pathology

Whereas acantholysis in Darier disease occurs primarily within discrete foci, the loss of intercellular bridges in HHD is generally more widespread within the epidermis. Thus, larger areas of dyscohesion with single or groups of acantholytic cells are seen, which have been likened to a "dilapidated brick wall". Dermal papillae, lined by a single layer of basal cells, protrude into the blister cavities and are referred to as "villi" (Fig. 59.17). In contrast to Darier disease, necrotic keratinocytes are uncommon, and only rare acantholytic dyskeratotic cells (e.g. "corps ronds") may be observed. In more chronic lesions, epidermal hyperplasia, parakeratosis, and focal crusts are found. A moderate perivascular lymphocytic infiltrate is observed in the superficial dermis.

Histologically, Grover disease may be indistinguishable from HHD, but these two entities are readily distinguished on the basis of clinical features. DIF is negative, thus excluding pemphigus vulgaris.

Differential Diagnosis

The blisters in HHD are typically fragile and rupture easily. Therefore, clinical experience and a high index of suspicion may be necessary to diagnose HHD, especially in patients with limited disease. Lesions confined to the axillae or groin may be mistaken for intertrigo or candidiasis (see Fig. 13.4). Isolated perianal maceration is easily misdiagnosed as irritant dermatitis, and vulvar involvement may resemble lichen simplex chronicus[78]. Histologic examination of affected skin is often the key to the diagnosis.

Downloaded for Anonymous User (n/a) at Egyptian Knowledge Bank from ClinicalKey.com by Elsevier on March 10, 2024. For personal use only. No other uses without permission. Copyright ©2024. Elsevier Inc. All rights reserved.

The lesions of inverse psoriasis have sharper borders, fewer erosions, and less crusting. A total skin examination, looking for additional sites of involvement and associated signs, e.g. nail pitting, will aid in the diagnosis. Vegetating intertriginous lesions in HHD may be identical to those of pemphigus vegetans (Hallopeau type) or pemphigoid vegetans, but the latter can be differentiated by positive DIF of perilesional skin.

The cutaneous features of HHD and Darier disease may overlap. Older reports described patients with characteristic skin findings of both genodermatoses who therefore carried two diagnoses[89], but genetic analysis can now establish a single diagnosis in such individuals. In general, the two disorders have different patterns of distribution that are fairly easily distinguished (see Fig. 59.4). Moreover, a predominantly vesicular eruption in patients with Darier disease is rare[20]. Additional features such as V-shaped notches in the distal free edge of the nail plate, longitudinal erythronychia, and oral papules point to the diagnosis of Darier disease.

Treatment

General measures

There is no specific therapy for the acantholysis. Wearing lightweight clothes is recommended to avoid friction and sweating, and adhesive dressings should be avoided. Colonization and secondary bacterial, fungal, and viral infections are addressed via antimicrobial cleansers or bleach baths and appropriate topical and/or systemic antimicrobial agents, respectively.

Topical and intralesional therapy

Topical corticosteroids often help to reduce inflammation and can be combined with topical antimicrobials and cleansers. Early application of corticosteroids may ameliorate flares[63], and injections of intralesional corticosteroids can be tried for persistent lesions. In order to minimize the potential side effects of topical corticosteroids in intertriginous zones (e.g. atrophy, striae, telangiectasias), the lowest potency that is effective should be used and they should be applied intermittently. Both improvement and worsening following treatment with topical calcineurin inhibitors have been described[90,91].

In case reports, improvement has been observed with topical application of 5-fluorouracil[92] and vitamin D analogues[93]. Of note, there are multiple reports of substantial improvement of HHD in the axillae, inframammary area, and groin after chemodenervation of sweat glands with botulinum toxin injections[94,95]. Application of zinc oxide paste in skin folds to protect against friction and moisture may also be helpful[90].

Surgical and physical therapy

Surgical therapy may be considered for disease unresponsive to general measures and topical treatments. While wide excision followed by grafting has been reported to be successful[96], this aggressive approach has been replaced by more superficial ablative techniques. The most well-documented method is dermabrasion[97], but laser vaporization of the epidermis (scanned CO_2 or erbium:YAG) seems to be equally effective[59]. Removal of the diseased epidermis plus its dermal niche of fibroblasts, which can extend to the level of the mid dermis, is recommended. Re-epithelialization from the spared adnexal structures normally occurs within 7–14 days. Benefit has also been reported with electron beam radiation[98], photodynamic therapy[99], and combination of narrowband UVB phototherapy with an oral retinoid[100].

Systemic therapy

With the exception of antimicrobial agents for secondary infections, there is no strong evidence to support the use of systemic therapies in HHD. A case series described improvement with long-term continuous or intermittent doxycycline administration in 6 patients with HHD[101], but the benefits of this treatment regimen vary (author's personal observations). Low-dose naltrexone may have some efficacy and is well-tolerated; results in case series have ranged from clinical improvement in 7 of 8 patients, with a 77% mean reduction in areas of involvement, to a sustained response in only 2 of 14 patients, with initial improvement then relapse in 6 and no response in 6 individuals[102]. Oral acitretin and isotretinoin also have variable efficacy[63], while successful results with alitretinoin have been reported in several patients[103]. There are anecdotal reports of severely affected individuals improving with the use of immunomodulatory drugs, e.g. prednisone, cyclosporine, methotrexate, dapsone, or afamelanotide[104–106]. In one case series, apremilast led to improvement in 4 patients (with relapse in 2 individuals after >6 months of treatment), but another report described no response to apremilast in 4 of 5 patients[107–109].

Copyright notice

Daniel Hohl retains copyright to his original photographs in Chapter 59.

Additional figures available in our eBook (see inside front cover for access code).

eFig. 59.1 Darier disease. Red–brown keratotic papules scattered on the abdomen. *Courtesy Julie V. Schaffer, MD.*

eFig. 59.4 Hailey–Hailey disease. Erythematous plaque with erosions and maceration of the inguinal canal and scrotum.

eFig. 59.2 Darier disease. Pink keratotic papules with areas of confluence on the chest and neck as well as scar centrally on the chest. *Courtesy Julie V. Schaffer, MD.*

eFig. 59.5 Hailey–Hailey disease. A, B Pink and pink–brown plaques with erosions and crusts. *Courtesy Jeffrey P. Callen, MD.*

eFig. 59.3 Darier disease. Nail changes with longitudinal erythronychia and notching of the free edge of the nail plate.

Downloaded for Anonymous User (n/a) at Egyptian Knowledge Bank from ClinicalKey.com by Elsevier on March 10, 2024. For personal use only. No other uses without permission. Copyright ©2024. Elsevier Inc. All rights reserved.